

News in Review

COMMENTARY AND PERSPECTIVE

RETINA

Bioengineered RPE Developed for Dry AMD

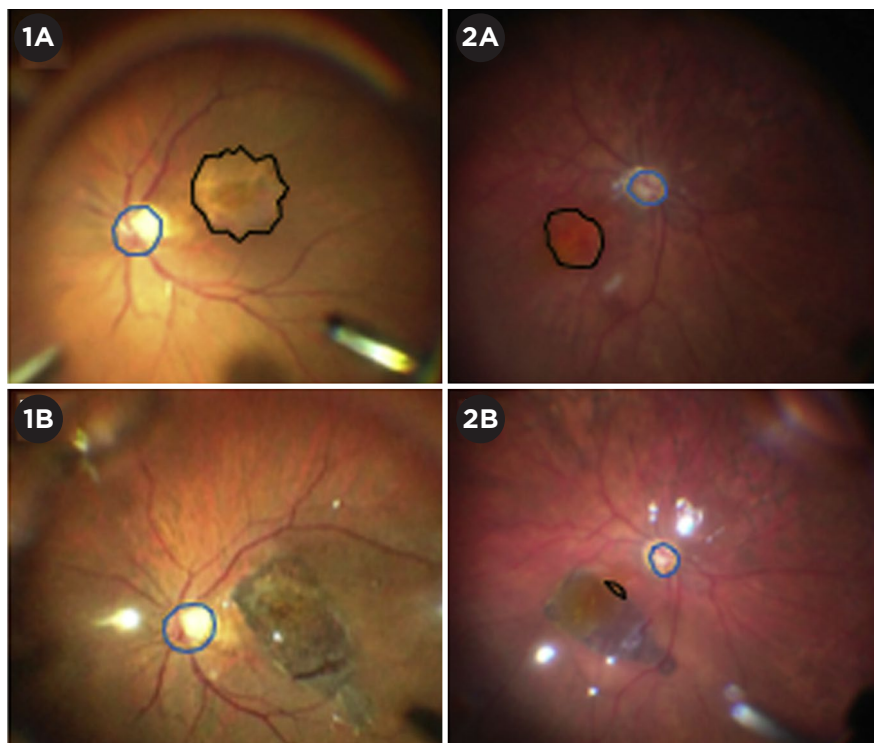
A BIOENGINEERED MONOLAYER OF retinal pigment epithelium (RPE), lying atop a synthetic Bruch membrane, can be safely and accurately implanted beneath sections of retina that have been damaged by geographic atrophy.¹

Researchers at the University of Southern California (USC) in Los Angeles hope this proof-of-principle clinical trial might be a step toward the first surgical treatment that could prevent, and perhaps reverse, the vision loss caused by the dry form of age-related macular degeneration (AMD), said researcher Mark S. Humayun, MD, PhD, at USC.

Study specifics. For this phase 1/2a safety study, lead coauthor Amir H. Kashani, MD, PhD—along with Dr. Humayun and the research team—implanted 3.5 × 6.25 mm sheets of polyethylene (a polymer) carrying polarized human embryonic stem cell–derived RPE into the eyes of 15 people with dry AMD.

In their report on the surgical, anatomic, and early safety outcomes of the procedure, the researchers noted the following:

- Using a special tool, the proprietary ultrathin carrier for the RPE cells could be folded and successfully inserted through an approximately 1-mm sclerotomy into a dissected retinal



BEFORE AND AFTER. Area of GA measured (1A, 2A) before and (1B, 2B) after implantation. In each case, most of the GA area is covered by the implant, signifying surgical success. Black outline = area of GA; blue outline = optic disc.

pocket, where the device remained stable perioperatively.

- The implantation failed in a 16th patient, apparently because of accumulated debris in the subretinal space during a long surgery.
- Intraoperative optical coherence tomography (iOCT) aided the surgeon in placing the device directly underneath the area of retinal damage, but iOCT was not necessary.
- The most common adverse events in the intra- and perioperative period were mild to moderate subretinal hemorrhages, which were asymptomatic.
- Surgical times ranged from 121-466 minutes (mean, 160 minutes), and they improved sufficiently with experience to suggest that the procedure could be performed on an outpatient basis.

Analysis of outcomes in the 15 patients after one year of follow-up is expected to be complete in time for presentation later this year at AAO 2020, Dr. Humayun said. An earlier report on the study's first four successful implantations suggested that the replacement RPE might carry visual benefits,² but data analysis needs to be completed on all implants for at least one year, he added.

Why an implant? This approach to ameliorating the vision loss of dry AMD differs in important ways from the approaches taken by others, Dr. Humayun said. For instance, why not inject RPE cells in suspension into these eyes? "Because other companies have looked at [injections] and determined that the cells don't line up,

they don't line up right side up, and they tend to clump rather than form a polarized monolayer in the subretinal space where they are needed," Dr. Humayun said. "We felt very strongly that we needed to implant these cells in the subretinal space on a scaffold."

The parylene material of the scaffold had to be custom engineered to mimic Bruch membrane, to be permeable to molecules that RPE cells require to survive, he said. "It allows the exchange of nutrients across the membrane."

Potential role. If intravitreal injections eventually gain approval for treatment of dry AMD, they might be used to prevent progression, Dr. Humayun said. "But if a patient has already progressed to a certain level of vision loss, or their disease is not really being slowed down, then you would need an implant to treat their condition."

—Linda Roach

1 Kashani AH et al. *Ophthalmol Retina*. 2020;4(3):264-273.

2 Kashani AH et al. *Sci Transl Med*. 2018;10(435).

Relevant financial disclosures—Dr. Humayun: Regenerative Patch Technologies: C,O,P; USC: E,P.

MALPRACTICE

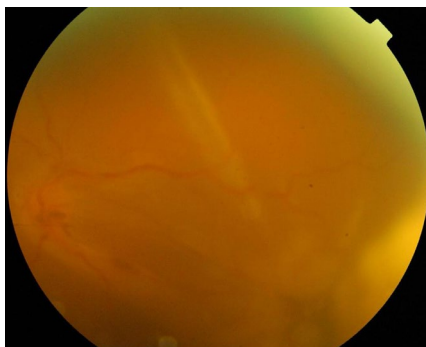
Safety Update: Ocular Anesthesia

ALTHOUGH ANESTHESIA-RELATED malpractice claims are relatively rare, serious injuries do occur. A retrospective review of the Ophthalmic Mutual Insurance Company (OMIC) database yielded 63 anesthesia-related closed claims by 50 patients, or 2.8% of total claims against OMIC's ophthalmologists, between 2008 and 2018.¹

"The review provides clarity about where we can make improvements," said Michael Morley, MD, ScM, at Ophthalmic Consultants of Boston and Harvard Medical School.

What went wrong? Globe perforation (n = 17) was the most common complication, followed by death (n = 13) and retrobulbar hemorrhage resulting in blindness (n = 7). Other adverse outcomes included optic nerve damage and vascular occlusions.

A clear majority of cases involved



PERFORATION. This patient developed endophthalmitis and retinal detachment following globe perforation during periocular anesthesia.

either retrobulbar or peribulbar anesthesia (64%; n = 16 each). General anesthesia was an alleged factor in four deaths, and sedation a factor in five.

The role of medical comorbidities. Nearly half the claims (48%) were associated with cataract surgery, followed by retina procedures (24%). Although the study wasn't structured to assess the inherent risk of assorted surgical procedures, Dr. Morley said type of surgery may not matter as much as the type of anesthesia or the severity of a patient's comorbidities. All but one of the 13 deaths occurred in patients who had preexisting significant comorbidities, notably diabetes and/or cardiovascular disease.

Avoiding adverse events. Although the researchers acknowledged that it is impossible to reduce the risk of anesthesia-related complications to zero, they provided a list of 10 recommendations for minimizing risk. Among them:

- Use the least invasive method of anesthesia when possible.
- Evaluate new anesthesia providers' skills in administering needle-based blocks.
- Consider pre-op testing and health optimization for patients with serious comorbidities or active medical problems.
- Manage perioperative anticoagulants in concert with the patient's other physicians.

Bottom line. "Ophthalmic anesthesia is generally very safe, but some patients undergo avoidable anesthesia-related complications," Dr. Morley said. "Our

job is to focus on these avoidable injuries using proven quality improvement methodology. The goal is to develop systems and workflows that lower the chance or opportunity of error and harm."

Procedure-specific consent forms, including those for anesthesia-related potential complications, are available at www.omic.com. —Miriam Karmel

1 Morley M et al. *Ophthalmology*. Published online Dec. 25, 2019.

Relevant financial disclosures—Dr. Morley: None.

PEDIATRICS

Handheld SD-OCT Validated in Infants

HANDHELD OPTICAL COHERENCE tomography (OCT) is a useful tool for imaging retinal thickness in infants. But is it a reliable one?

Researchers at Duke University in Durham, North Carolina, found that measurements taken with a handheld spectral-domain OCT (SD-OCT) system match the reproducibility and reliability of those taken with tabletop SD-OCT machines.¹ "We are happily surprised by this finding. We were actually expecting less reproducibility with handheld OCTs," said Xi Chen, MD, PhD. She added, "Many factors could affect measurements in handheld OCT, including—but not limited to—alignment, hand motion, and infant eye movement." However, those problems did not arise.

Handheld versus tabletop. For this retrospective review, the researchers included 21 unselected preterm infants whose foveas were imaged with the handheld device (Envisu C2300, Leica/Bioptigen). Those results were compared to 25 adults scanned with tabletop SD-OCT (Leica/Bioptigen).

Central foveal thickness (CFT) measurements were analyzed by both an expert grader and a typical grader (defined as one who was certified but had less experience).

Agreement with some variation. There was excellent agreement between expert and typical graders on measurements from either imaging system. The

CORNEA

CXL: Not for Fungal Keratitis?

SOME CORNEA SPECIALISTS ARE ALREADY USING corneal cross-linking (CXL) plus antifungal medications to treat moderate filamentous fungal ulcers. But a recent study suggests that this strategy may be ineffective.¹ Moreover, CXL in these patients may result in decreased visual acuity (VA).

Although some evidence has suggested potential benefits of CXL for treating bacterial and fungal keratitis, “more robust evidence was necessary,” said Jennifer Rose-Nussbaumer, MD, at the University of California, San Francisco.

As a result, she said, “We designed this trial to evaluate the benefit in fungal keratitis,” which can be particularly challenging to treat.

Study design. The study was conducted at Aravind Eye Hospital in Madurai, India. Out of 403 patients with smear-positive ulcers, 111 were randomized to one of the following four treatments: 1) topical natamycin 5% alone, 2) topical natamycin plus CXL, 3) topical amphotericin B 0.15% alone, and 4) topical amphotericin plus CXL.

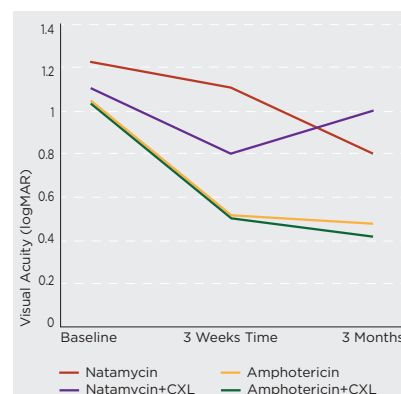
The primary outcome of the trial was microbiological cure at 24 hours on repeat culture. Secondary outcomes included best spectacle-corrected VA (BSCVA) at three weeks and three months; percentage of study participants with epithelial healing at three days, three weeks, and three months; infiltrate or scar size at three

weeks and three months; and adverse events.

Outcomes. The researchers found no benefit to adjuvant CXL in the treatment of filamentous fungal ulcers. “Specifically, we found no improvement in microbiological cure including culture and smear, no improvement in infiltrate or scar size, no increase in the percentage epithelialized at three weeks or three months, and no difference in adverse events,” they stated. These results did not vary depending on whether patients received natamycin or amphotericin.

Moreover, the results suggest that adjuvant CXL may have a negative effect on VA. At three weeks, BSCVA was approximately 2.2 Snellen lines worse among those receiving CXL; at three months, BSCVA in those receiving CXL was approximately 3.2 Snellen lines worse. The reason for this is unclear, the researchers said.

—Arthur Stone



IMPACT ON VISION. Vision declined in all treatment arms after controlling for baseline BSCVA.

1 Prajna NV et al. *Ophthalmology*. 2020;127(2):159-166.

Relevant financial disclosures—Dr. Rose-Nussbaumer: None.

graders did, however, find a greater range in infant CFT measurements compared with adults. This was expected because of foveal changes during development. In premature infants, the fovea is shallow, the retinal layers are

thin, and there is a lack of photoreceptor sublayers. As the fovea matures, it deepens and the retinal layers thicken. Despite these distinctions in the developing eye, it was notable how reproducible CFT measurements were, Dr.

Chen said.

Multiple applications. The results have implications for clinical use as well as for studies, particularly when evaluating infants, uncooperative children, and bedridden adults.

At Duke, pediatric ophthalmologists and pediatric retina spec-

ialists have become more reliant on handheld SD-OCT to evaluate the retina and optic nerve in infants and young children, both in the clinic and the OR.

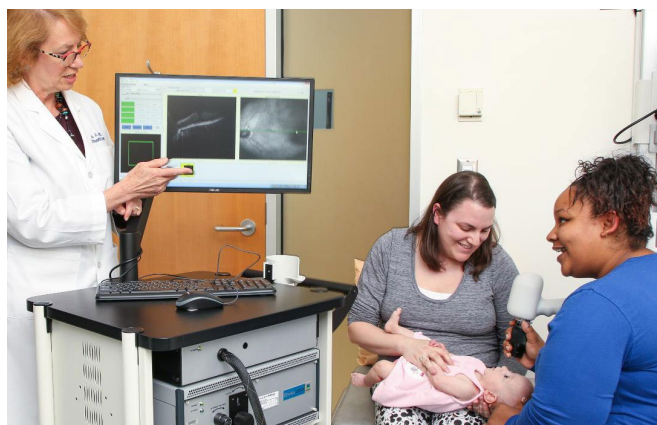On another front, a prospective study is underway comparing handheld and tabletop instruments in healthy adult volunteers. Handheld instruments could be used in adults who are bedbound or in the ICU as well as in those who otherwise cannot cooperate or follow instructions.

Regarding the current study, Dr. Chen said, “Although it was limited by its retrospective nature, it provided promising results and paved the foundation for future studies evaluating the infant retina.”

—Miriam Karmel

1 Wang KL et al. *PLoS One*. Published online Dec. 11, 2019.

Relevant financial disclosures—Dr. Chen: None.



IN THE CLINIC. (Left) Cynthia A. Toth, MD, oversees the assessment of a child with handheld SD-OCT at Duke.